



PATIENT

Marshal Whitfield

SPECIES

Feline

BREED

DLH

SEX

Male Neutered

AGE

6 years

WEIGHT

14.8lbs

INTERPRETED BY

Maggie Machen Lamy,
 DVM DACVIM
 (Cardiology)

IMAGING PERFORMED BY

Crystal Hill, RVT

HOSPITAL NAME

Hillview VC

REFERRING VET

Dr. Stevenson

INVOICE

45867

DATE

11/20/25

PRESENTING CLINICAL SIGNS

History: Grade 2/6 heart murmur. Asymptomatic.

ECHOCARDIOGRAM FINDINGS

2D, m-mode, color flow and doppler imaging is available. The left ventricular wall is normal. There is a mildly hyperechoic endocardium. The papillary muscles appear remodeled. No significant hypertrophy seen. The left atrium is mildly dilated and bulbous in appearance. The mitral valve is normal in structure and mobility. No MR. The right atrium is normal. The right ventricle is normal. No TR. Blood flow through the RVOT are normal in velocity. No pleural or pericardial effusion seen. No obvious cardiac tumors.

CARDIAC CHART

FELINE CARDIAC PARAMETERS	BODY WEIGHT (kg)	HR (BPM)	IVSd (cm) (Moise, Pipers)	LVIDd (cm) (Moise, Pipers)	LVWd (cm) (Moise, Pipers)	FS (%)	EF (%)
NORMAL PARAMETER	-----	150-240	0.35-0.55	<2 (mean 1.5)	3.5-0.55	35-67	80-100
PATIENT	6.7	220	0.46	1.4	0.47	55	80
FELINE CARDIAC PARAMETERS	LA/AO (Boon)	LA/AO HEART BASE (Swe) (Abbott)	LA 2D short axis Base view (cm) (Abbott)		LVOT VEL (m/s)	RVOT VEL (m/s)	E max (m/s)
NORMAL	<1.5	<1.3	<1.2		<1.6	<1.3	<0.9
PATIENT	NM	1.5	1.66		NM	1.4	NM

**Note: All measurements based upon multi-modal images and methods. An average value is reported.*
 Adapted from June Boon, Veterinary Echocardiography, 1998
 Abbott J & MacLean H JVIM 2006;20: 111-119, Moise et al. Am J Vet Res 47:1476, 1986. Pipers et al. Am J Vet Res 40:882, 1979.

INTERPRETATION OF THE FINDINGS & FURTHER RECOMMENDATIONS

Early unclassified cardiomyopathy is suspected. This diagnosis is based upon mild left atrial dilation and a lack of significant LV pathology. A normal variant cannot be ruled out; however, is considered less likely. Fortunately, with only mild atrial dilation the risk for complication is low; however, there may be risk for progression going forward. No cause for the murmur is identified in this study, making it likely physiologic in origin.

Many cats with cardiomyopathy will remain occult/asymptomatic for extended periods of time, however there is a subset that will experience more rapid progression to clinical signs in the first few years after diagnosis. Monitoring for progression will help dictate long-term prognosis, which is guarded at this stage.

Given only mild atrial dilation, no medications are indicated at this time. Monitor for any signs of progressive heart disease at home including change in breathing rate or effort, signs of a blood clot event and/or lethargy/syncope going forward.

Anesthetic risk is considered mildly elevated, with risk for fluid overload, spontaneous CHF, hypotension, etc. Judicious IV fluid rates are advised to avoid fluid overload. Drugs that stimulate



PATIENT

Marshal Whitfield

SPECIES

Feline

BREED

DLH

SEX

Male Neutered

AGE

6 years

WEIGHT

14.8lbs

INTERPRETED BY

Maggie Machen Lamy,
DVM DACVIM
(Cardiology)

IMAGING PERFORMED BY

Crystal Hill, RVT

HOSPITAL NAME

Hillview VC

REFERRING VET

Dr. Stevenson

INVOICE

45867

DATE

11/20/25

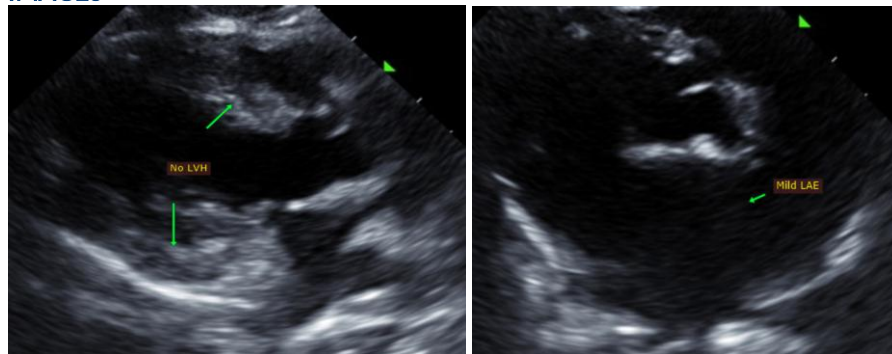
heart rate should be avoided unless clinically necessary (glycopyrrolate, atropine). Avoid ketamine, telazol, acepromazine and Dexdomitor. A reasonable protocol would include opioid/benzodiazepine pre-medication, propofol induction, isoflurane gas. Avoid steroids if possible. If fluid therapy is needed for kidney disease, close monitoring of breathing rates is advised as fluid intolerance is certainly a possibility.

PLAN

Baseline BP is recommended.

Recommend recheck echocardiogram in 6 months to screen for progression, sooner if clinical signs arise.

IMAGES



The information and recommendations provided are based on the images presented by the referring veterinarian. No evaluation can be communicated regarding pathology that was not visible in the image/video clips provided.

Thank you for this referral. This report was generated using transcription software, and minor dictation errors may be present. If the clinical or image interpretation does not parallel your findings or if I can be of any further assistance, please contact me.

Maggie Machen Lamy, DVM
Diplomate of the American College of Veterinary Internal Medicine (Cardiology)
info@sonopath.com